

Total Contact Casting of the Diabetic Foot in Daily Practice

A prospective follow-up study

MARRIGJE H. NABUURS-FRANSSSEN, MD¹
 RON SLEEGERS²
 MAYA SP HUIJBERTS, MD, PHD¹
 WIEL WIJNEN²

ANTAL P. SANDERS, MD, PHD³
 GEERT WALENKAMP, MD, PHD⁴
 NICOLAAS C. SCHAPER, MD, PHD¹

OBJECTIVE — A limited number of clinical trials have shown that the total contact cast (TCC) is an effective treatment in neuropathic, noninfected, and nonischemic foot ulcers. In this prospective data collection study, we assessed outcome and complications of TCC treatment in neuropathic patients with and without peripheral arterial disease (PAD) or (superficial) infection.

RESEARCH DESIGN AND METHODS — Ninety-eight consecutive patients selected for casting were followed until healing; all had polyneuropathy, 44% had PAD, and 29% had infection. Primary outcomes were percentage healed with a cast, time to heal, and number of complications.

RESULTS — Ninety percent of all nonischemic ulcers without infection and 87% with infection healed in the cast (NS). In patients with PAD but without critical limb ischemia, 69% of the ulcers without infection and 36% with infection healed ($P < 0.01$). In multivariate analyses, PAD, infection, and heel ulcers were associated with a lower percentage healed (all $P < 0.05$). Median duration of cast treatment was 34 days. New ulcers, all superficial, developed in 9% and preulcerative lesions in 28% of the patients; these skin lesions healed in the cast within a maximum of 13 days.

CONCLUSIONS — In comparison to pure neuropathic ulcers, ulcers with moderate ischemia or infection can be treated effectively with casting. However, when both PAD and infection are present or the patient has a heel ulcer, outcome is poor and alternative strategies should be sought. The high rate of preulcerative lesions stresses the importance of close monitoring during TCC treatment.

Diabetes Care 28:243–247, 2005

Off-loading of the wound is one of the key elements in treating diabetic (neuropathic) foot ulcers (1). Several off-loading devices are available, such as walkers, half shoes, orthoses, felted foam, and the total contact cast (TCC) (2–5), which is seen as the definitive standard therapy (2,6–8). There are three randomized clinical trials (6–8) published on the effectiveness of TCCs in neuropathic plantar foot ulcers, in which a nonremovable TCC was compared with no off-

loading (6), a removable aircast walker (7), and/or a shoe modality (8). These studies concluded that a TCC healed a higher proportion of neuropathic, noninfected ulcers in a shorter amount of time, with healing rates of ~90%.

Although a TCC seems a highly attractive off-loading modality, several disadvantages have been reported: new ulcers may occur, daily wound care is not possible, mobility is impaired, costs may be relatively high, and specialized staff seems necessary (3). In the case of prolonged casting, joint rigidity and muscular atrophy have been documented (7). Finally, the above described trials were performed in centers of excellence in patients with superficial, noninfected, nonischemic, plantar ulcers, and numbers were relatively small. When combined, these published randomized controlled trials reported on 66 patients treated with TCC. Although from a biomechanical point of view off-loading is indicated in most patients, only a minority of all patients fulfills the aforementioned criteria (9). Therefore, in many patients, the presence of peripheral arterial disease (PAD) and/or infection will be seen as a contraindication for casting. In addition, fear of complications and lack of educated staff hamper the implementation of TCC in daily clinical practice. A recent European survey revealed that TCC is indeed used in a minority of specialized diabetic foot centers (Eurodiale Study Group, unpublished data).

The present study was undertaken to determine the outcome and complication rate of TCC in a wide range of diabetic foot ulcers in daily practice. Patients with moderate PAD and/or (superficial) infection were included in order to compare the outcome of TCC treatment in these patients with the outcome in patients with noninfected pure neuropathic ulcers.

RESEARCH DESIGN AND METHODS

All individuals, starting from the first patient treated, were included in the prospective data collection

From the ¹Department of Internal Medicine and Endocrinology, University Hospital Maastricht, Maastricht, the Netherlands; the ²Casting Clinic, University Hospital Maastricht, Maastricht, the Netherlands; the ³Department of Rehabilitation Medicine, University Hospital Maastricht, Maastricht, the Netherlands; and the ⁴Department of Orthopedics, University Hospital Maastricht, Maastricht, the Netherlands.

Address correspondence and reprint requests to Marrigje H. Nabuurs-Franssen, University Hospital Maastricht, Department of Internal Medicine and Endocrinology, P.O. Box 5800, Maastricht 6200 AZ, Netherlands. E-mail: m.nabuurs-franssen@intmed.unimaas.nl.

Received for publication 29 May 2004 and accepted in revised form 26 October 2004.

Abbreviations: PAD, peripheral arterial disease; RCC, removable total contact cast; SMC, shoe-model cast; TCC, total contact cast.

A table elsewhere in this issue shows conventional and Système International (SI) units and conversion factors for many substances.

© 2005 by the American Diabetes Association.

The costs of publication of this article were defrayed in part by the payment of page charges. This article must therefore be hereby marked "advertisement" in accordance with 18 U.S.C. Section 1734 solely to indicate this fact.

Cast	TCC (N=50)	RCC (N=22)	SMC (N=26)
Picture			
Weight (gram)	700	700	250
Indication:			
compliance	poor	good	good
exsudation	-	+++	+++
walking pattern	-	-	small steps*
daily wound inspection/care	-	+	+
Contra-indication:			
compliance	-	poor	hyperpronated foot, need for support ankle fixation
foot characteristics	-	-	
ulcers at margin foot	+	+	-

Figure 1—Cast characteristics. *Patients were instructed to walk with small steps because this cast is associated with higher mobility.

study, which commenced in January 1998 and ended in March 2003. Eligible were all diabetic patients with polyneuropathy and a foot ulcer in whom off-loading was indicated but not possible with simple measures (e.g., felt). Exclusion criteria were critical limb ischemia (ankle pressure <50 mmHg, toe pressure <30 mmHg, TcPO₂ < 30 mmHg) (10,11) and major illnesses affecting wound healing. Patients with infection higher than grade 2 of the PEDIS system (10) were also excluded, with the exception of four patients who were treated with oral antibiotics for a chronic osteomyelitis without other signs of infection. Results of the first cast treatment are reported, and patients with a bilateral cast were not analyzed. Data were collected on a weekly or bi-weekly basis until healing or when casting was stopped before healing. Cast treatment was terminated when there was no reduction in wound size or depth during 4 consecutive weeks, when an infection greater than grade 2 (10) developed, or when the patient had severe discomfort with the cast. These cases are all defined as cast failure. The patient remained in the cast until healing, which was defined as an intact skin on clinical examination.

Complications were scored on each visit, which included discomfort, chafed skin, preulcerative lesion (defined as a non-ulcerative lesion related to local pressure in the cast), new ulcers on the affected foot, and lower-extremity joint problems. Time to heal was defined as the number of days from baseline until healing in the cast.

Patients were treated by a multidisciplinary team. At every visit, patient characteristics, cast details, and complications were registered electronically. Peripheral polyneuropathy was defined (10) as the absence of two of five sensory modalities (vibration sensation using the 128-Hz tuning fork, light touch, blunt-sharp dis-

crimination, Achilles tendon reflex, and 10-g monofilament). Moderate PAD was defined (10) as the absence of both pedal pulses on the affected foot and/or presence of intermittent claudication and/or ankle brachial index <0.9 and/or toe brachial index <0.6 and/or TcPO₂ 30–60 mmHg, without signs of critical limb ischemia (see above). The anatomical location (35 regions of the foot) was defined as described by Apelqvist et al. (12). The wound surface was estimated (10) by multiplying the largest by the second largest diameter, measured perpendicular to the first diameter. Superficial infection was defined (10,11) as an infection involving skin and subcutaneous tissue only, without systemic signs. At least two of the following items were present: local swelling or induration, erythema >0.5 cm around the ulcer, local tenderness or pain, local warmth, purulent discharge (thick, opaque to white or sanguineous secretion), and lymphangitis (10,11).

Three total contact casting modalities were used: a nonremovable TCC, a removable TCC (RCC), and a shoe-model cast (SMC) that could not be removed by the patient. These casts were applied using a modification of the technique described by Kominsky (13), and the choice of cast was based on both patient and cast characteristics (Fig. 1). Eighty-six percent of the patients were treated with one type of cast during the complete treatment period. In the other patients, one specific type of cast was prescribed >60% of the time, and this cast was used in the analyses. Felt was applied around the ulcer to reduce peak pressure. Patients with a removable cast were instructed to remove the device only during wound care. At every visit, necrotic tissue and callus were surgically debrided. TCCs were renewed every 1–2 weeks, and RCC and SMC devices were modified if necessary.

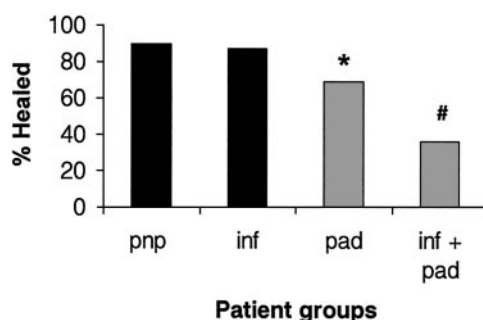


Figure 2—The effect of PAD and infection on outcome of cast treatment. pnp, presence of peripheral neuropathy, no signs of infection of PAD; inf, presence of infection, no signs of PAD; pad, presence of PAD, no signs of infection; inf + pad, presence of both infection and PAD. *P < 0.01 pad patients versus pnp patients; #P < 0.005 inf + pad patients versus pnp patients.

Table 1—Patient characteristics of all patients and patients with cast failure and healing ulcers

Patient characteristics	All (n = 98)	Cast failure (n = 24)	Healed (n = 74)
Age (years)	67 (55–76)	71 (56–78)	64 (55–73)
Sex (% male)	65	71	63
Duration diabetes (years)	18 (7–24)	15 (10–25)	19 (7–24)
PAD (%)	44	75*	34
Percent with type 2 diabetes	70	68	73
Ulcer characteristics			
Size (cm ²)	1.3 (0.6–7.1)	1.3 (0.4–19.5)	1.2 (0.6–3.1)
Duration (days)	31 (28–145)	61* (28–145)	21 (7–74)
Infection (%)	29	46*	24
Location (%)			
Dig 1 plantar	22	8	27
MTH 1 plantar	15	0*	20
Ray 2, 3, 4 plantar	30	30	30
Ray 5 plantar	14	21	11
Dorsum /midfoot	9	12	8
Heel	9	29*	3

Data are median (interquartile range). * $P < 0.05$.

Statistical analyses

Data are expressed as median and interquartile ranges. Comparisons were performed using Fisher's exact, Mann-Whitney U , and Kruskal-Wallis tests. In all analyses, correction was made for ulcer duration. Multivariate analyses were performed to further delineate the effect of PAD and infection on the percentage healed and cast failure (logistic regression). In this analysis we included PAD, infection at baseline, type and duration of diabetes, age and sex, size and duration of the ulcer at baseline, and type of cast. The SPSS statistical package, version 11.0 (Chicago, IL), was used.

RESULTS—Ninety-eight patients were enrolled in the study. More than 90% of these patients had multiple diabetic complications. Patient and wound characteristics are described in Table 1. PAD was present in 44% and infection at baseline in 29% of the patients. Overall, healing was achieved in 74 (76%) of the patients, with a median healing time of 33 days (interquartile range 14–63). In 22 patients, the ulcer did not heal during cast treatment (cast failure). Nine of these patients developed progressive infection, six were hospitalized for intravenous antibiotics, and three underwent amputation (two lower leg, one toe). Because of impaired healing, a revascularization procedure was performed in two patients and a free-flap transplantation in three patients.

In seven patients, casting was stopped due to discomfort with the cast and non-compliance in one patient. In all the aforementioned patients, alternative off-loading techniques were used, which resulted in healing of 20 of the 22 ulcers at the end of the study period. Two patients were lost to follow-up before healing had occurred and were included in the analyses as cast failures ($n = 24$ in total).

Ulcer healing

In patients without infection and without PAD, healing occurred in 90%, and in patients without PAD but with infection, healing was observed in 87% (NS) (Fig. 2). In patients without infection but with moderate PAD, healing occurred in 69% ($P < 0.01$ vs. PAD-negative/infection-negative patients). However, in patients with infection and PAD, healing was markedly impaired; only 36% of the ulcers healed during cast treatment ($P < 0.005$ vs. PAD-negative/infection-negative patients). The time to heal was 18 days in the patients without infection and without PAD (range 10–41 days) and 29 days in patients without PAD but with infection (range 27–68 days; $P < 0.05$). In patients without infection but with moderate PAD, the time to heal was 42 days (range 14–65 days; $P < 0.05$ vs. PAD-negative/infection-negative patients and PAD-negative/infection-positive patients). Because only a minority of patients with infection and PAD healed

during cast treatment, the numbers were too small to calculate the time to heal.

No differences in age, sex, duration of diabetes, type of diabetes, diabetic complications, and ulcer size were observed between the patients who healed and the patients who did not heal in the cast (Table 1). Moreover, no differences were observed between the healing rates of the three types of cast (TCC vs. RCC vs. SMC). Patients with cast failure had, in comparison with patients in whom the ulcer healed, more frequent moderate PAD (75 vs. 34%; $P < 0.001$), longer duration of the ulcer (61 vs. 21 days; $P < 0.05$), and more frequent infection at baseline (46 vs. 24%; $P < 0.05$). In addition, the anatomical location was clearly related to outcome; all ulcers ($n = 15$) in the metatarsal head 1 region healed, irrespective of the presence of PAD and/or infection. In contrast, the minority of heel ulcers healed ($P < 0.02$) (Table 1). Logistic regression analysis also showed that infection at baseline (OR 3.6), PAD (OR 7.4), and the location at the heel (OR 11.4) were associated with a lower percentage of healing in the cast.

Complications

New ulcers, all superficial, were observed in 9% of the patients and were not related to ischemia, infection, or the anatomical location of the primary ulcer (data not shown). These ulcers healed within a maximum of 13 days in a revised cast. Preulcerative lesions developed in 28% of the patients but resolved within a few days after minor adaptations of the cast. Chafed skin was found in 8% of the patients, and temporary joint problems were reported in 7% of the patients.

CONCLUSIONS—Increased biomechanical stress is one of the most important pathways leading to ulceration in patients with neuropathic and neuroischemic foot ulcers. Randomized clinical trials (6–8) have shown that casting can be an effective off-loading modality in the treatment of neuropathic, noninfected ulcers, but several questions remain about the applicability of these data to daily practice. The current study shows that with casting, in a wide range of ulcers, the majority of patients (76%) can be healed in a relative short time span (median 33 days). As expected, the best results were obtained in patients with noninfected, pure neuropathic ulcers. Ninety percent

of the ulcers healed in a median of 18 days; these results are comparable with the aforementioned randomized controlled trials in which TCC was evaluated (6–8). These healing rates of ~90% compare favorably with the results obtained in the control arms of randomized controlled trials (14,15) on wound care, in which ~30% healed in 140 days, as summarized in a meta-analysis (16). In the current study, superficial infection in patients with pure neuropathic ulcers did not influence the results, but in patients with neuroischemic ulcers without infection, the percentage healed was somewhat lower (69% healed). The poorest results were obtained in patients with both neuroischemia and infection (36% healed).

Infection is a frequent complication of diabetic foot ulcers (11), and the presence of infection greatly enhances the risk of amputation (17). At present, infection is seen as a contraindication for total contact casting (8,18), given the risks of spreading of the infection, the inability of daily wound inspection, and the need for daily dressing changes. Indeed, infection did have negative effects on healing rates and healing times, although this effect was small in pure neuropathic ulcers. Therefore, it appears that casting can be applied in infected neuropathic ulcers with results comparable with pure neuropathic ulcers without infection, in the absence of PAD or deep tissue infection. Prerequisites are close monitoring of the patient, weekly wound care, and antibiotic treatment. In case of increased exudation, a removable cast can be safely used because this technique allows daily dressing changes.

Approximately 40% of the foot ulcers in Westernized countries are neuroischemic. PAD is usually seen as a contraindication for total contact casting (18), because of fear of further deterioration of the blood supply and development of new ulcers. However, some authors reported that this treatment was efficacious in small numbers of patients (19,20). Elevated biomechanical stress is probably as important in neuroischemic as in neuropathic foot ulcers (21); therefore, off-loading is indicated in both types of ulcers. Our data show that in comparison with pure neuropathic ulcers, TCC treatment can be used with limited loss of effectiveness in neuroischemic ulcers,

without critical limb ischemia and infection.

The combination of infection and moderate PAD renders a poor prognosis. In the current study, only 36% of the patients with this combination healed with casting. These poor healing rates are in line with an amputation rate of 50% in patients with infection and peripheral ischemia, as reported earlier (22). It is likely that the peripheral perfusion deficit resulted in impaired penetration of the antibiotics (23) and possibly contributed to a decreased local immune response. Therefore, other treatment modalities should be used in these types of ulcers.

The anatomical location of the ulcer affected healing rates in our study (24–27). All ulcers at the metatarsal head 1 region healed, and very poor results were obtained in patients with heel ulcers. As suggested by previous biomechanical studies (28), the TCC technique is not very effective in reducing elevated plantar pressures at the heel region, and therefore, alternative off-loading strategies should be sought (29). The duration of the ulcer had a negative effect on the time to heal, as also shown in other studies on wound healing (16). Therefore, we suggest that in patients in whom casting is considered, this treatment should be started as soon as possible.

In addition to the classic rigid TCC, we used two semi-rigid adaptations that were less heavy and that permitted daily wound care: a RCC up to the knee and a SMC up to the ankle that was fixated. The nonremovable TCC and the RCC were similar in many aspects, and earlier studies did not show a difference in pressure relief between these two modalities (30,31). As suggested earlier (32), part of the efficacy of the nonremovable TCC is possibly related to the “forced compliance” for off-loading. We did not observe major differences in the results obtained with these devices; however, our study was not designed to evaluate the efficacy of these different off-loading techniques. Additional studies are needed to determine the (cost-)effectiveness of these more recently developed casting models versus the classic TCC.

In the published randomized controlled trials, TCC was associated with a low complication rate (6–8), but this does not mean that similar results will be obtained in daily practice. Our study shows that casting in the elderly and fre-

quently frail patient with a diabetic foot ulcer is indeed applicable in daily practice and can contribute to a favorable outcome of treatment. All consecutive patients were included from the first day we started casting; therefore, our data include the learning curve of the staff. Moreover, casts were applied during the years of the study by seven different casting technicians. Casting therapy is not without risks, as illustrated by the 9% new ulcers and the 29% preulcerative lesions in the current study. However, these adverse events did not result in delayed healing of the foot, as all ulcers and preulcerative lesions resolved in the cast before the primary ulcer had healed. These complications were not related to the presence of infection, PAD, or the anatomical location of the ulcer but were probably the result of suboptimal casting technique and/or inappropriate use of the cast by the patient. The high number of preulcerative lesions caused by the cast stresses the importance of close monitoring until the last day of treatment.

In conclusion, casting therapy is applicable in daily practice in a wide range of patients, with good healing rates and relative few major complications. In comparison with patients with pure neuropathic ulcers, patients with (superficial) infection or moderate PAD can be treated with limited loss of effectiveness with casting. However, given the poor outcome, alternative strategies should be used in patients with the combination of PAD and (superficial) infection and in patients with heel ulcers.

References

1. Jeffcoate WJ, Harding KG: Diabetic foot ulcers. *Lancet* 361:1545–1551, 2003
2. Spencer S: Pressure relieving interventions for preventing and treating diabetic foot ulcers (Cochrane review). *Cochrane Database Syst Rev* 3:CD002302, 2000
3. Armstrong DG, Lavery LA: Evidence-based options for off-loading diabetic wounds. *Clin Podiatr Med Surg* 15: 95–104, 1998
4. Armstrong DG, Stacpoole-Shea S: Total contact casts and removable cast walkers. Mitigation of plantar heel pressure. *J Am Podiatr Med Assoc* 89:50–53, 1999
5. Cavanagh PR, Ulbrecht JS, Caputo GM: New developments in the biomechanics of the diabetic foot. *Diabetes Metab Res Rev* 16 (Suppl. 1):S6–S10, 2000
6. Mueller MJ, Diamond JE, Sinacore DR, Delitto A, Blair VP III, Drury DA, Rose SJ:

- Total contact casting in treatment of diabetic plantar ulcers: controlled clinical trial. *Diabetes Care* 12:384–388, 1989
7. Caravaggi C, Faglia E, De Giglio R, Mantero M, Quarantiello A, Sommariva E, Gino M, Pritelli C, Morabito A: Effectiveness and safety of a nonremovable fiberglass off-bearing cast versus a therapeutic shoe in the treatment of neuropathic foot ulcers: a randomized study. *Diabetes Care* 23:1746–1751, 2000
 8. Armstrong DG, Nguyen HC, Lavery LA, van Schie CH, Boulton AJ, Harkless LB: Off-loading the diabetic foot wound: a randomized clinical trial. *Diabetes Care* 24:1019–1022, 2001
 9. International Working Group on the Diabetic Foot. *International Consensus on the Diabetic Foot*: Apelqvist J, Bakker K, Van Houtum WH, Nabuurs-Franssen MH, Schaper NC, Eds. Maastricht, the Netherlands, 1999
 10. Schaper NC: Diabetic foot ulcer classification system for research purposes: a progress report on criteria for including patients in research studies. *Diabetes Metab Res Rev* 20 (Suppl. 1):S90–S95, 2004
 11. Lipsky BA: A report from the International Consensus on Diagnosing and Treating the Infected Diabetic Foot. *Diabetes Metab Res Rev* 20 (Suppl. 1):S68–S77, 2004
 12. Larsson J, Agardh CD, Apelqvist J, Stenstrom A: Clinical characteristics in relation to final amputation level in diabetic patients with foot ulcers: a prospective study of healing below or above ankle in 187 patients. *Foot Ankle Int* 16:69–74, 1995
 13. Kominsky SJ: The ambulatory total contact cast. In *The High Risk Foot in Diabetes Mellitus*. 1st ed. RG Frykberg, Ed. New York, Churchill Livingstone, 1991, p. 449–455
 14. Embil JM, Papp K, Sibbald G, Tousignant J, Smiell JM, Wong B, Lau CY: Recombinant human platelet-derived growth factor-BB (becaplermin) for healing chronic lower extremity diabetic ulcers: an open-label clinical evaluation of efficacy. *Wound Repair Regen* 8:162–168, 2000
 15. Gentzkow GD, Iwasaki SD, Hershon KS, Mengel M, Prendergast JJ, Ricotta JJ, Steed DP, Lipkin S: Use of Dermagraft, a cultured human dermis, to treat diabetic foot ulcers. *Diabetes Care* 19:350–354, 1996
 16. Margolis DJ, Kantor J, Berlin JA: Healing of diabetic neuropathic foot ulcers receiving standard treatment: a meta-analysis. *Diabetes Care* 22:692–695, 1999
 17. Eneroth M, Apelqvist J, Stenstrom A: Clinical characteristics and outcome in 223 diabetic patients with deep foot infections. *Foot Ankle Int* 18:716–722, 1997
 18. Laing PW, Cogley DI, Klenerman L: Neuropathic foot ulceration treated by total contact casts. *J Bone Joint Surg Br* 74:133–136, 1992
 19. Sinacore DR, Mueller MJ, Diamond JE, Blair VP III, Drury D, Rose SJ: Diabetic plantar ulcers treated by total contact casting: a clinical report. *Phys Ther* 67:1543–1549, 1987
 20. Borssen B, Lithner F: Plaster casts in the management of advanced ischaemic and neuropathic diabetic foot lesions. *Diabet Med* 6:720–723, 1989
 21. Pitei DL, Lord M, Foster A, Wilson S, Watkins PJ, Edmonds ME: Plantar pressures are elevated in the neuroischaemic and the neuropathic diabetic foot. *Diabetes Care* 22:1966–1970, 1999
 22. Armstrong DG, Lavery LA, Harkless LB: Validation of a diabetic wound classification system: the contribution of depth, infection, and ischemia to risk of amputation. *Diabetes Care* 21:855–859, 1998
 23. Raymakers JTFJ, Houben AJ, Van der Heyden JJ, Tordoir JHM, Kitslaar PJEHM, Schaper NC: The effect of diabetes and severe ischemia on the penetration of ceftazidime into tissues of the limb. *Diabet Med* 18:229–234, 2001
 24. Sinacore DR: Healing times of diabetic ulcers in the presence of fixed deformities of the foot using total contact casting. *Foot Ankle Int* 19:613–618, 1998
 25. Lavery LA, Vela SA, Lavery DC, Quebedeaux TL: Total contact casts: pressure reduction at ulcer sites and the effect on the contralateral foot. *Arch Phys Med Rehabil* 78:1268–1271, 1997
 26. Wertsch JJ, Frank LW, Zhu H, Price MB, Harris GF, Alba HM: Plantar pressures with total contact casting. *J Rehabil Res Dev* 32:205–209, 1995
 27. Walker SC, Helm PA, Pullium G: Total contact casting and chronic diabetic neuropathic foot ulcerations: healing rates by wound location. *Arch Phys Med Rehabil* 68:217–221, 1987
 28. Shaw JE, Hsi WL, Ulbrecht JS, Norkitis A, Becker MB, Cavanagh PR: The mechanism of plantar unloading in total contact casts: implications for design and clinical use. *Foot Ankle Int* 18:809–817, 1997
 29. Cevera JJ, Bolton LL, Kerstein MD: Options for diabetic patients with chronic heel ulcers. *J Diabetes Complications* 11:358–366, 1997
 30. Lavery LA, Vela SA, Lavery DC, Quebedeaux TL: Reducing dynamic foot pressures in high-risk diabetic subjects with foot ulcerations: a comparison of treatments. *Diabetes Care* 19:818–821, 1996
 31. Fleischli JG, Lavery LA, Vela SA, Ashry H, Lavery DC: 1997 William J Stickel Bronze Award: comparison of strategies for reducing pressure at the site of neuropathic ulcers. *J Am Podiatr Med Assoc* 87:466–472, 1997
 32. Armstrong DG, Lavery LA, Kimbriel HR, Nixon BP, Boulton AJ: Activity patterns of patients with diabetic foot ulceration: patients with active ulceration may not adhere to a standard pressure off-loading regimen. *Diabetes Care* 26:2595–2597, 2003